

Liberal Approach in Finger and Hand Replantation and Revascularization

REDA M. AHMAD, M.D.

The Plastic and Reconstructive Surgery Unit, Faculty of Medicine, Zagazig University, Zagazig, Egypt

ABSTRACT

Background: Hand and fingers amputations can cause significant morbidity and disability. The microsurgery technique added an important revolution in replantation surgery. This research paper aims to describe through case-based discussion, the current microsurgical replantation procedures of hand and fingers and the eventual outcomes that can be achieved.

Patients and Methods: Within four years, 51 patients from 10 different governments of Egypt represented with hand, thumb, index, middle finger, little finger or multiple finger amputation. All cases managed with microsurgery replantation.

Results: There were no significant association between smoking and incidence of complications, incidence of second procedure or ability of doing daily activity. Significant association presented between the good preservation and success of replantation. Duration of ischemia ranged from 2 to 16 hours (5.12 ± 1.99) and is positively related to incidence of complication and reduce operations or secondary procedures. The mean value of DASH score was significantly higher in hand replantation than that of thumb and other digits replantation. However, no significant difference detected between thumb and other digits replantation. Return of active motion ($54\% \pm 14.29$) significantly associated with the ability of doing daily activity.

In Conclusion: The type of injury (crush or guillotine) and ischemia time affect the success rates of the replantation surgeries. The nature of injury is the maximum important factor both in success rates and functional results. Lengthy ischemia time declines the success rates of replantation.

Key Words: Microsurgery – Hand – Fingers – Replantation.

INTRODUCTION

Revascularization of partly detached digits was established to be possible in the clinical situation by Kleinert and Kasdan in 1965 [1]. The first replantation of a detached limb was carried out more than 50 years ago by Malt in Boston when he replanted the totally severed arm of a 12-year-old boy [2]. The first successful thumb replantation was achieved by Komatsu and Tamai in Japan, as described in 1968 [3]. Subsequently, replantation of amputated extremities has considered an accept-

ed technique [4-6], especially after the finest microsurgical technique added an important element in stopping arterial or venous occlusion [7].

Indeed, there is ample disagreement concerning the indications and contraindications for digital replantation [8-11]. In spite of that, a replanted thumb offers the greatest reconstruction obtainable [12]. Several finger amputations remain reconstructive problems that might be hard to correct deprived of replantation of one or all of the severed digits [12,13].

Every hand amputation beginning from zone III (distally) to zone V (proximally) offers the chance of realistic function after replantation, frequently higher to accessible prostheses [14,15].

Replantation surgery is inspiring because the surgeon has to perform precise work rapidly [16].

The aim of this work is to evaluate the results of replantation of the amputated fingers and hands of received cases in the period of study and area of the study, and to analyze these results in correlation to age of the cases, method of preservation, and smoking.

PATIENTS AND Methods

In the period between November 2012 to May 2016, 51 patients 49 males (96.08%) and 2 females (3.02%) from 10 different governments of Egypt (majority from Sharkiyah and 10th of Ramadan (60.78%). Patient's age ranged from 1 to 76 years old (mean \pm SD) (28.37 ± 14.18). 34 (66.67%) patient were smokers.

10 cases (19.6%) were amputated hand, "7 dominant hand and 3 non dominant" (6 of them were total amputation and the other 4 were near total). 6 hands were crushed and the other 4 were guillotine amputation.

16 cases (31.37%) were thumb amputation "8 dominant and 8 non dominant" (10 of them were total amputation and the other 6 were near total). 7 thumbs were crushed, the 7 were guillotine injured and 2 were avulsed.

6 cases (11.76%) were index amputation "3 dominant hand and 3 non dominant" (4 of them were total amputation and the other 2 were near total). 4 indices were crushed, one was guillotine injured and one was firearm injured.

2 cases (3.92%) were middle finger amputation "both were dominant" (1 of them was total amputation and the other was near total). One was crush and the other was guillotine.

2 cases (3.92%) were little finger amputation "one was dominant and the other was non dominant" (1 of them was total amputation and the other was near total).

15 cases (29.41%) were multiple finger amputation "46 fingers" "32 dominant hand and 14 non dominant" (23 of them were totally amputated and the other 23 were near total). 26 fingers were crushed and 20 fingers were guillotine injured.

The duration of ischemia ranged from 2 hours to 16 hours with mean \pm SD (5.12 ± 1.99).

Operative data:

Ethical committee permission was granted for this study (approved by the Institutional Review Board and Ethics Committee of Faculty of Medicine-Zagazig University) and written consent of patients was also taken.

In most of the cases, replantation was performed under general anesthesia with a tourniquet on the affected upper limb in first steps of surgery. In some of the cases combinations of continuous inter scalene block and light anesthesia were done.

1- *Wash, debridement of the unhealthy tissues, and radical resection:* Particularly in crush injuries were of vital significance. Amputated parts were washed with 500ml of sterilized lactated Ringer's solution with 80mg of gentamicin. These parts were then cautiously debrided under the magnification, shortening of the bone according to the necessity and bone destruction, enables primary vessels, nerves, and tendons restoration.

2- *Exploration and Identification of the tissues in the amputated segments and in the proximal portions* was done systematically, vessels and nerves declared and marked with an 8/0 nylon suture.

3- *Microsurgical evaluation of the vessels* was achieved. Ribbon signs in the arteries denoted inappropriate fragment for repair. Any hurt to the intima required its excision. Minor hematomas on the arterial wall specified side branches avulsion. If these problems were present, suturing or resection of a segment was done. Subcutaneous hematomas on back aspect of fingers suggested the location of vein interruption. Dorsal venous arcades were recognized and used in repair [17,18].

4- *Bone fixation and musculotendinous avulsion management:* The cases were fixed by K. wires, and in patients of amputation at the wrist joint we did our best to preserve certain joint task. Tendons were fixed to muscle bellies or tendon transfer to substitute avulsed tendon in avulsion amputation with total destruction of muscles.

5- *Restoration of the extensor tendons:* Extensor tendons were sutured with two sutures (horizontal mattress) of 4-0 polypropylene.

6- *Flexor tendons repair:* The flexor tendons were sutured with 3-0 polypropylene using the suture method of Tajima [19].

7- *Repair of one or two veins:* To decrease incidence of congestion.

8- *Arterial reconstruction.* Primary arterial repair was probable only next to shortening of bone. Superficial vein grafts from the front of distal part of same side forearm were used in some cases with fingers replantation. Before arterial anastomosis, blood stream was established from the proximal end of the artery.

9- *Venous reconstruction.* After arterial anastomosis, primary end-to-end vein anastomosis of double number of the arteries which had been anastomosed. Relocating marginally one end of a venous arcade present adjacent to wound was a noble answer in digital vein defects 2cm or less.

10- *Nerve reconstruction:* Neurorrhaphy was done using epineural sutures to both median and ulnar nerve and their branches using 9/0 nylon suture.

11- *Skin closure and drainage* were done with light bandage; the hand was placed in a plaster splint in anticlaw position for 10-21 days. Postoperative management: Postoperative medications were identical for patients (according to age and medical status and fluid charts), and include broad spectrum antibiotics, metronidazole for 7 days, low molecular weight heparin for 5 days, aspirin 75mg/day for 10 days, analgesic in the form of pethidine in the first 48 hours then paracetamol

for 7 days. K wires were removed after 4-6 weeks guided by clinical and radiological signs of initial healing. Physiotherapy started 10 days postoperative and continued for 4-6 months [20].

Assessment:

The postoperative results as regard the form were evaluated as regard function the following points were evaluated:

- A- The general performance of the patient using his replanted hand and his overall satisfaction by noting his work stability.
- B- The recovery of flexor and extensor mobility of digits by measuring the total active motion.
- C- The recovery of thumb opposition.
- D- Recovery of sensitivity of the fingers supplied by median and ulnar nerve by using the 2 point discrimination test.
- E- The ability to do daily activity by allowing the patient to hold objects of different shape and dimension, writing, picking up a coin and buttoning.
- F- The operated cases returned for testing that consisted of an interview using a patient-centered questionnaire (the Disabilities of the Arm, Shoulder and Hand (DASH) score) and physical examinations of the range of motion [21].

Statistical analysis:

Data were analyzed by Statistical Package of Social Science (SPSS), software version 22.0 (SPSS Inc., 2013). Continuous data were expressed as Mean \pm SD, while the nominal data were presented by the frequency and percentage.

The one-way analysis of variance (ANOVA): Is used to determine whether there are any significant differences between the means of two or more independent (unrelated) groups. Least significance difference (LSD): It is one of the post hoc tests. It is used for multiple comparisons between groups. It was calculated at different probability values. The chi-square test of association: Is used to discover if there is a relationship between two categorical variables. The Fisher's exact test: Is used instead of a chi-square test if one or more of the cells has an expected frequency of five or less. Pearson's correlation analysis was performed to screen potential relations between duration of ischemia and incidence of complication. p -value < 0.05 considered significant.

RESULTS

There were a variety of cases received, and operated on. 51 patients received (10 hands, 16 thumbs, 6 indices, 2 middle fingers, 2 little fingers, and 15 patients with 46 fingers amputation). The overall success rate was 81.7%.

There were no significant association between smoking and incidence of complications, incidence of second procedure or ability of doing daily activity (p -values of Fisher's exact test were 0.13, 0.55 and 0.66 respectively). In addition, p -values of Pearson Chi-square were 0.09, 0.46 and 0.50 respectively). In fact smoking was forbidden from the moment of receiving of the patient and all through the management.

Significant association presented between the good preservation and success of replantation as p value of Fisher's exact test is 0.026 and p -value of Pearson Chi-square is 0.015.

Duration of ischemia ranged from 2 to 16 hours (5.12 ± 1.99) and is positively related to incidence of complication and reduce operations or secondary procedures ($p=0.04$).

DASH score in general, ranged from 10 to 64 with mean \pm SD (25.71 ± 12.22). The mean value of DASH score was significantly higher in hand replantation than that of thumb and other digits replantation ($p=0.008$ and 0.004 respectively). However, no significant difference between thumb and other digits replantation (Table 1).

Regarding two point discrimination, in general it was ranged from 7 to 12 with mean \pm SD (9.36 ± 1.28). There was no significant difference between replantation of hand, thumb or other digits ($p > 0.05$) (Table 2).

Return of active motion ranged generally from 30 to 80% ($54\% \pm 14.29$) and significantly associated with the ability of doing daily activity ($p=0.02$). There was no significant difference between replantation of hand, thumb or other digits ($p > 0.05$) (Table 3).

Table (1): Statistical analysis of DASH scores among hand, thumb and multiple digits replantation.

DASH score	Hand N=10	Thumb N=16	Digits N=25	All cases N=51
Range	30-45	10-35	11-64	10-64
\bar{X}	34.20	18.56	23.2	25.71
SD	13.019	11.60	15.7	12.22
F	3.858 ($p=0.027$)			
p -value of LSD VS hand		0.008	0.04	
p -value of LSD VS thumb			0.30	

Table (2): Statistical analysis of average two points discrimination/mm among hand, thumb and multiple digits replantation.

Average two points discrimination/mm	Hand N=10	Thumb N=16	Digits N=25	All cases N=51
Range	8-12	7-11	8-10	7-12
\bar{X}	9.00	7.00	7.64	9.36
SD	3.43	3.63	4.019	1.28
F	0.86 ($p=0.429$)			
p -value of LSD VS hand		0.197	0.343	
p -value of LSD VS thumb			0.60	

Table (3): Statistical analysis of total active motion in comparison to intact side among hand, thumb and multiple digits replantation.

% of total active motion VS intact side	Hand N=10	Thumb N=16	Digits N=25	All cases N=51
Range	45-70	20-60	35-80	20-80
\bar{X}	55.00	37.50	45.40	54
SD	21.98	18.52	22.95	14.29
F	2.06 ($p=0.138$)			
p -value of LSD VS hand		0.048	0.238	
p -value of LSD VS thumb			0.256	

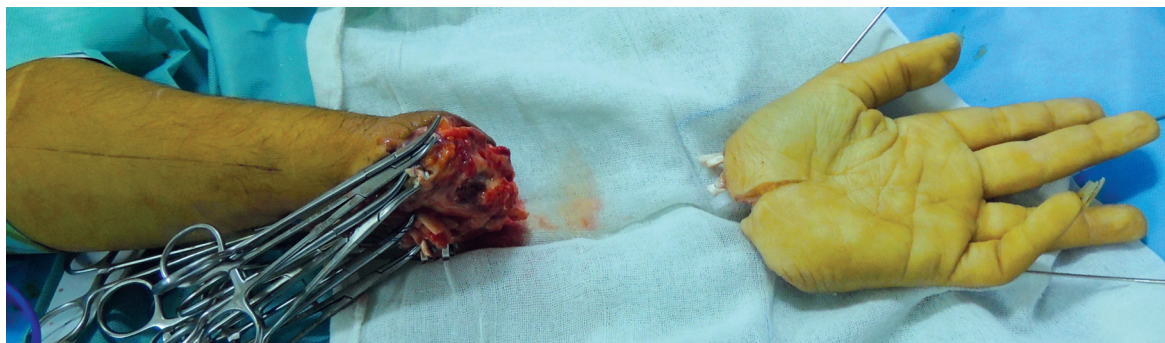


Photo (1): Guillotine amputated hand, intraoperative.

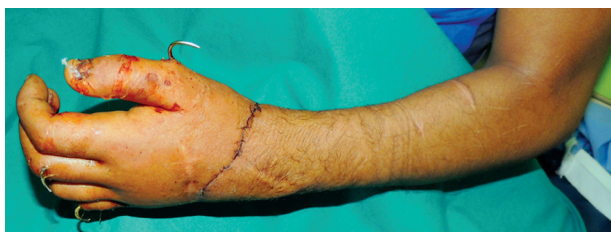

Photo (2): Post-operative replanted hand.

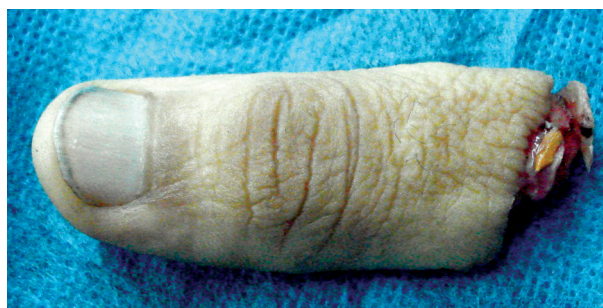

Photo (3): Preoperative amputated left thumb.

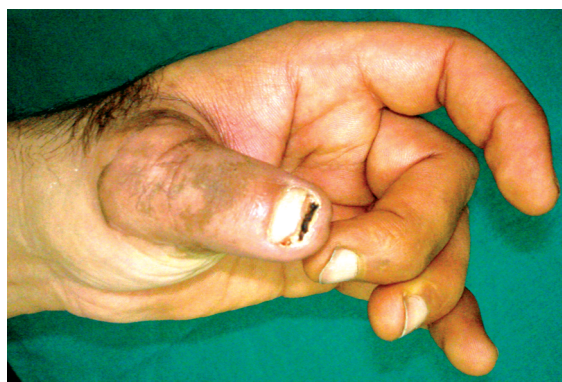

Photo (4): Post-operative replanted left thumb.

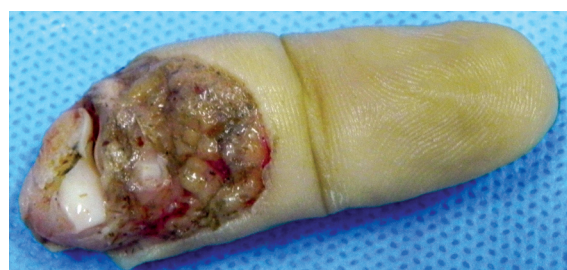

Photo (5): Preoperative amputated left index.

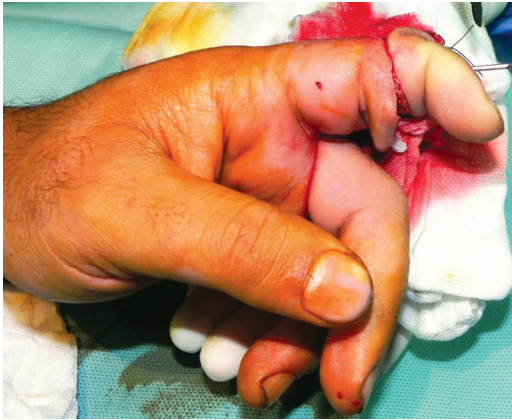

Photo (6): Intra-operative replanted left index.

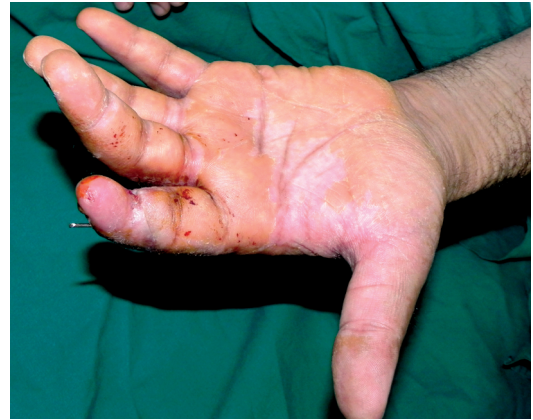

Photo (7): Post-operative replanted left index.

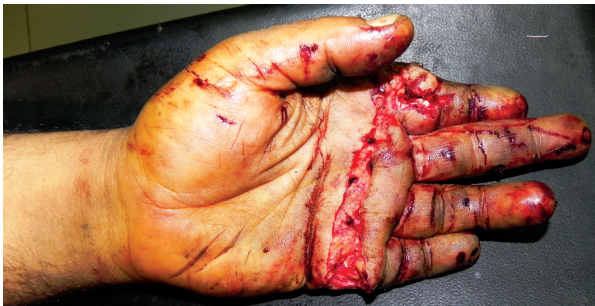

Photo (8): Crush incomplete amputated four fingers.

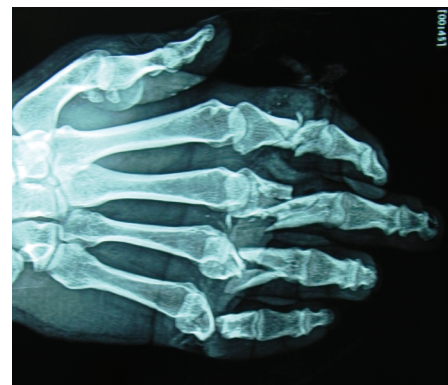

Photo (9): Preoperative X-ray of crush incomplete amputated four fingers.

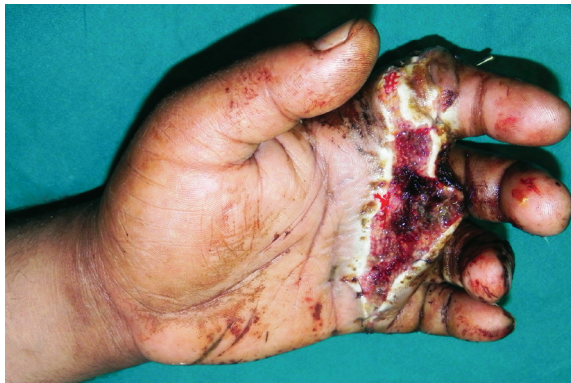

Photo (10): Early postoperative replantation of four fingers.

DISCUSSION

The capability of hand micro surgeon in selecting the perfect way of the management of amputation of fingers and hands, is important for success of replantation and ultimate functional results of the treatment [22].

Finger amputation occurring at occupation represents one of the commonest traumatic lesions of the hand [23,24], that affects age of work and

production, specifically in industries and agriculture field [25].

A lot of authors argue that the conventional indications for digital replantation have been established by experience, should consider the possibility for long-standing function, and had better be followed in most if not all cases [8,18,26].

In spite of that, particular surgeons have been assuming a further liberal approach and seek to replant most of amputated fingers [27,28].

For instance, efficient replantation after avulsion amputations or amputation of trivial parts of fingers are constantly more achieved with the liberal usage of vein grafts, free flaps, comprising venous arterialized flaps, with arteriovenous fistulas [29,30].

In addition to the growing microsurgical and supermicrosurgical experience have permitted to replant several digits and digital parts that would be believed unachievable in the past [28,30].

Therefore, the traditional indications and contraindications for digital replantation mentioned

in classical textbooks are being increasingly challenged in many medical centers [28,31].

This liberal approach was adopted in a great part of this study, as replantation of a single finger, revascularization of crushed or avulsed fingers, and replantation and revascularization in extreme of ages.

The replantation of amputated digit has come to be a dependable method, with success rates stated to be more than 90%. Venous insufficiency remains the commonest complication after replantation with stated incidence of 7-32% [32].

In spite of the disharmony of cases in this study, the calculated overall success rate was 81.7%. Some authors presented their results with avulsion injury replantation having lower overall survival rates (66%) than the approximated 80-90% survival in non avulsion cases [33,34].

Regarding single finger amputations, a great agreement in literature that replantation of a single finger in adults other than the thumb should not be performed [8,9,11].

Bad results perceived in the long term follow-up, chiefly stiffness that impedes moving of the residual digits [9,11,18].

In other word, this concept is true in index finger amputation, as the brain has a habit to ignore this finger and replaces the middle finger for thumb-middle finger pinch [9,11].

However, a lot of researchers have described patients with single finger replantation rather than the thumb with good outcomes in intellectual and well-motivated persons [18].

From 51 cases studied in this work, 10 patients with single finger replantation rather than the thumb was achieved. The success rate of replantation revascularization was 70%, with overall improvement parameters of good to fair results.

So the idea of considering that, the single absolute contraindication of replantation revascularization surgery is the patient's adverse general condition. That mean he cannot withstand extended complex surgery [35], this idea was clear in making the decision in the cases presented in this study.

Soucacos et al., assessed the functional outcome of 67 successfully replanted single-digit amputations, and determined that the indications for replantation of a single-digit amputation should be as follows: 1) Amputation distal to the insertion

of the flexor digitorum superficialis; 2) Ring injuries type II and IIIa; and 3) Amputations at the level of or distal to the DIP joint [36].

Moreover, studies by Kay et al., [37] and Sanmartin et al., [38] stated no functional difference concentrated on the level of amputation in relative to the PIP joint. In other words, a study by Urbaniak et al., [39] reported reduced range of motion with replantation of whole avulsion injuries whether or not the amputation was proximal or distal to the FDS insertion.

When the amputation happened at the level of the DIP joint, replantation revealed benefits including a single-stage practice, satisfactory sensibility lacking painful neuroma, respectable metacarpophalangeal and PIP joint motion, and a cosmetically beautiful outcome in comparison to conservative stamp plasty [40]. Conversely, it is quite hard to attain acceptable functional results in cases of replantation or revascularization at the level of the PIP joint. Avulsion amputations at the PIP joint [41]. Thus, many surgeons decided that replantation of the amputated single finger proximal to insertion of flexor digitorum superficialis was seldom indicated [42]. Nevertheless, the minute a case with finger amputation proximal to the PIP joint desires to undergo replantation surgery, what we should do? in the experience of Hattori et al., their study described that, in spite of poorer mobility in PIP replantation, cases can obtain a pinch function if the finger can be fixed in a useful position. Satisfactory PIP joint fixation makes DASH score and hand function more better [21].

Although vascular diameters are much smaller in small children, this circumstance does not impede arterial and microvascular venous anastomosis, and the lengthy surgical time is acceptable. Children have superior capacities for adaptation and functional regaining.

In some reports a lower survival rates of thumb avulsion injuries (68%) was stated, may be due to the more accepted practice of trying more practically tough replantation with thumb avulsion injuries, somewhere the state for replantation may be little promising. Boulas [33], establish that the mean survival of whole finger avulsion replants is 78%. The functional results after replantation of finger avulsion injuries are superior to what is usually mentioned "poor" by many reviewers [33,43,44].

Urbaniak et al., [39] described that, the overall practice of replanting avulsion injuries outcomes in poor hand function. However Small et al., [45] establish a reverse opinion in many situations.

Scheker et al., [46] stated most of their cases except the patient with bilateral amputation had a good grip and pinch motion which permitted them to do maximum daily events as writing, buttoning and holding different things.

In conclusion, the type of injury (crush avulsion or guillotine) and ischemia time affect the success rates of the replantation surgeries. The nature of injury is the maximum important factor both in terms of success rates and functional results. Lengthy ischemia time somewhat declines the success rates of replantation. The indications and contraindications for replantation should be revised.

REFERENCES

- 1- Kleinert H.E. and Kasdan M.L.: Anastomosis of digital vessels. *J. Ky. Med. Assoc.*, 63: 106, 1965.
- 2- Malt R.A.: Clinical aspects of restoring limbs. *Adv. Surg.*, 2: 19, 1966.
- 3- Komatsu S. and Tamai S.: Successful replantation of a completely cut-off thumb. *Plast. Reconstr. Surg.*, 42: 374, 1968.
- 4- Berger A. and Millesi H.: Functional results from replantation surgery: A five year report from the Viennese replantation team. *Aust. N. Z. J. Surg.*, 50: 244, 1980.
- 5- Zhong-Wei C., Meyer V.E., Kleinert H.E. and Beasley R.W.: Present indications and contraindications for replantation as reflected by long-term functional results. *Orthop. Clin. North Am.*, 12: 849, 1981.
- 6- Tamai S.: Twenty years' experience of limb replantation: Review of 293 upper extremity replants. *J. Hand Surg. (Am.)*, 7: 549, 1982.
- 7- Renaud B., Langlais F., Colmar M. and Thomazeau H.: Digital reimplantation and revascularization, factors of preservation. 183 fingers. *Ann. Chir. Main. Memb. Super*, 10 (5): 385-98, 1991.
- 8- Pederson W.C.: Replantation. *Plastic and Reconstructive Surgery*, 107 (3): 823-41, 2001.
- 9- Chang J. and Jones N.: Twelve simple maneuvers to optimize digital replantation and revascularization. *Techniques in Hand & Upper Extremity Surgery*, 8 (3): 161-6, 2004.
- 10- Cavadas P.C.: Multi-level replantation of the palm and digits. *Plastic and Reconstructive Surgery*, 122 (2): 95e-6e, 2008.
- 11- Bastidas N., Cassidy L., Hoffman L. and Sharma S.: A single-institution experience of hand surgery litigation in a major replantation center. *Plastic and Reconstructive Surgery*, 127 (1): 284-92, 2011.
- 12- Jones J.M., Schenck R.R. and Chesney R.B.: Digital replantation and amputation: Comparison of function. *J. Hand. Surg. (Am.)*, 7: 183, 1982.
- 13- Steinau H.U. and Biemer E.: Status of replantation: Indications and limits in hand surgery. *Langenbecks Arch. Chir. Suppl. II Verh. Dtsch. Ges. Chir.*, 751, 1990.
- 14- Blomgren I., Blomqvist G., Ejekskar A., Fogdestam I., Volkman R. and Edshage S.: Hand function after replantation or revascularization of upper extremity injuries: A follow-up study of 21 cases operated on 1979-1985 in Goteborg. *Scand. J. Plast. Reconstr. Surg. Hand Surg.*, 22: 93, 1988.
- 15- Goldner R.D. and Urbaniak J.R.: Indications for replantation in the adult upper extremity. *Occup. Med.*, 4: 525, 1989.
- 16- Lee B.I., Chung H.Y., Kim W.K., Kim S.W. and Dhong E.S.: The effects of the number and ratio of repaired arteries and veins on the survival rate in digital replantation. *Ann. Plast. Surg. Mar.*, 44 (3): 288e94, 2000.
- 17- Jones N.F.: Replantation in the upper extremity. In: Thorne C.H., Beasley R.W., Aston S.J., Bartlett S.P., Gurtner G.C., Spear S.L., editors. *Grabb & Smith's plastic surgery*. 6th ed. USA: Lippincott Williams & Wilkins, p. 868-83, 2007.
- 18- Goldner R.D. and Urbaniak J.R.: Replantation. In: Wolfe S.W., Hotchkiss R.N., Pederson W.C., Kozin S.H., editors. *Green's operative hand surgery*. 6th ed. Philadelphia: Elsevier Churchill Livingstone, 1585-601, 2011.
- 19- Tajima T.: History, current status, and aspects of hand surgery in Japan. *Clinical Orthopaedics and Related Research*, (184): 41-9, 1984.
- 20- EL-Sherbiny K.M., Aboulwafa A.M., Nasser S. and Zakria K.S.: Hand Replantation Following Complete Amputations. A study of both form and functional outcome. *Egypt, J. Plast. Reconstr. Surg.*, 33 (2): 291-6, 2009.
- 21- Hattori Y., Doi K., Ikeda K. and Estrella E.P.: A retrospective study of functional outcomes after successful versus amputation closure for single fingertip amputations. *J. Hand Surg.*, 31A: 811-8, 2006.
- 22- Molski M.: Replantation of fingers and hands after avulsion and crush injuries. *Journal of Plastic, Reconstructive & Aesthetic Surgery*, 60: 748e-54, 2007.
- 23- Livingston D.H., Keenan D., Kim D., Elcavage J. and Malangoni M.A.: Ex-tent of disability following traumatic extremity amputation. *J. Trauma.*, 37 (3): 495-9, 1994.
- 24- Dillingham T.R., Pezzin L.E. and MacKenzie E.J.: Limb amputation and limb deficiency: Epidemiology and recent trends in the United States. *South Med. J.*, 95 (8): 875-83, 2002.
- 25- Janmohammadi N.: Epidemiological features of extremity traumatic amputation in Babol, North of Iran. *Journal of Orthopaedics*, 5 (2): e6897, 2008.
- 26- Soucacos P.N.: Indications and selection for digital amputation and replantation. *Journal of Hand Surgery, (Edinburgh, Lothian)*, 26 (6): 572-81, 2001.
- 27- Dos Remedios C., Leps P. and Schoofs M.: Results of 46 digital replantations, with a minimal follow-up of one year. *Chirurgie de la Main*, 24 (5): 236-42, 2005.
- 28- Cavadas P.C., Landin L. and Thione A.: Secondary ectopic transfer for replantation salvage after severe wound infection. *Microsurgery*, 31 (4): 288-92, 2011.
- 29- Cavadas P.C.: Salvage of replanted upper extremities with major soft-tissue complications. *Journal of Plastic, Reconstructive & Aesthetic Surgery*, 60 (7): 769-75, 2007.

- 30- Cavadas P.C.: Multilevel replantation of the palm and digits. *Plastic and Reconstructive Surgery*, 122 (2): 95e-6e, 2008.
- 31- Sebastin S.J. and Chung K.C.: A systematic review of the outcomes of replantation of distal digital amputation. *Plastic and Reconstructive Surgery*, 128 (3): 723-37, 2011.
- 32- Levin L.S. and Cooper E.O.: Clinical use of anticoagulants following replantation surgery. *J. Hand. Surg. Am.*, Oct., 33 (8): 1437-9, 2008.
- 33- Boulas H.J.: Amputations of the fingers and hand: Indications for replantation. *J. Am. Acad. Orthop. Sur.*, 6: 100-5, 1998.
- 34- Medling B.D., Bueno R.A. Jr., Russell R.C. and Neumeister M.W.: Replantation outcomes. *Clin. Plast. Surg.*, 34: 177-85, 2007.
- 35- Li J., Guo Z., Zhu Q., et al.: Fingertip replantation: Determinants of survival. *Plast. Reconstr. Surg.*, 122 (3): 833-9, 2008.
- 36- Soucacos P.N., Beris A.E., Touliatos A.S., Vekris M., Pakos S. and Varitimidis S.: Current indications for single digit replantation. *Acta. Orthop. Scand. Suppl.*, 264: 12-5, 1995.
- 37- Kay S., Werntz J. and Wolff T.W.: Ring avulsion injuries: Classification and prognosis. *J. Hand. Surg. Am.*, 14: 204-13, 1989.
- 38- Sanmartin M., Fernandes F., Lajoie A.S. and Gupta A.: Analysis of prognostic factors in ring avulsion injuries. *J. Hand. Surg. Am.*, 29: 1028-37, 2004.
- 39- Urbaniak J.R., Roth J.H., Nunley J.A., Goldner R.D. and Koman L.A.: The results of replantation after amputation of a single finger. *J. Bone Joint Surg. Am.*, 67: 611-9, 1985.
- 40- Davis S.E. and Chung K.C.: Replantation of finger avulsion injuries: A systematic review of survival and functional outcomes. *J. Hand Surg. Am.*, 36 (4): 686-94, 2011.
- 41- Erika D.S. and Kevin C.C.: Replantation of finger avulsion injuries: A systematic review of survival and functional outcomes. *J. Hand Surg. Am.*, 36 (4): 686-94, 2011.
- 42- Waikukul S., Sakkarnkosol S., Vanadurongwan V. and Un-nanuntana A.: Results of 1018 digital replantations in 552 patients. *Injury*, 31: 33-40, 2000.
- 43- Merle M. and Dautel G.: Advances in digital replantation. *Clin. Plast. Surg.*, 24: 87-105, 1997.
- 44- Ross D.C., Manktelow R.T., Wells M.T. and Boyd J.B.: Tendon function after replantation: Prognostic factors and strategies to enhance total active motion. *Ann. Plast. Surg.*, 51: 141-6, 2003.
- 45- Small J.O., Brennen M.D. and Colville J.: Early active mobilization following flexor tendon repair in zone 2. *J. Hand Surg. Br.*, 14: 383-91, 1989.
- 46- Schecker L.R., Chesher S.P., Netscher D.T., et al.: Functional results of dynamic splinting after trans-metacarpal, wrist and distal forearm replantation. *J. Hand. Surg.*, 20B: 584e90, 1995.